

Treatment for displaced Tillaux fractures in adolescent age group[☆]

Mohamed Ebrahim Ali Al-Ashhab^{a,*}, Ashraf Atef Mahmoud Mohamed^b

^a Orthopedics and Traumatology Department, Benha Faculty of Medicine, Benha University, Egypt

^b Orthopedics and Traumatology Department, Tanta Faculty of Medicine, Tanta University, Egypt

ARTICLE INFO

Article history:

Received 11 January 2019

Received in revised form 14 March 2019

Accepted 2 April 2019

Keywords:

Tillaux
Fracture
Epiphyseal injury
Distal end tibia
Juvenile fracture

ABSTRACT

Background: Around age 11–15 years, a forced external rotation of the foot in a supination or a medial rotation of the leg on the fixed foot usually is responsible for an avulsion injury to the anterolateral epiphysis, known as Tillaux fracture. Ligamentous injuries are rare in children because ligaments are stronger than is the growth plate that frequently is injured.

Objective: The aim of this study was to present the clinical outcome until the end of growth after surgical treatment for displaced adolescent Tillaux fractures.

Patients and methods: 13 patients with Tillaux fractures in the adolescent age group. Patient's age ranged (12–17 years) with an average 13.4 years. Of those 13 patients, there were 9 females and 4 males.

Results: Fracture union was obtained in all cases (100%) and was assessed radiologically when X-ray check-ups in all projections showed the significant presence of trabeculation crossing the fracture, without pain and functionally using the American Orthopedic Foot and Ankle Society (AOFAS) score of the ankle joint. Overall average score was 97 ranged 95–100. There was no recorded post-operative complication.

Conclusion: The plain radiographs of patients with an avulsion injury of anterolateral tubercle (Tillaux fragment) should be carefully examined for evidence of syndesmotic widening. If there is any doubt, CT scans is helpful. If fracture displacement was greater than 2 mm, a surgical intervention is recommended to restore the normal anatomy of the ankle joint. Anatomically reduced Tillaux fractures at adolescent age group either by closed or opened means, followed by post-operative plaster cast immobilization will lead to excellent results.

© 2019 European Foot and Ankle Society. Published by Elsevier Ltd. All rights reserved.

1. Introduction

Approximately 15% of all adolescent injuries of the long bones involve the epiphyseal growth plate, and 2.9% of these are Tillaux fractures [1]. The physis of the distal tibia accounts for 18% of the overall limb length and 32% of the overall growth of the tibia. The distal tibial physis closes at about 15 years of age in girls and 17 in boys. Closure begins centrally, extends medially, and then laterally over 18 month period. This asymmetric closure sequence leads to the characteristic adolescent transitional fractures of the ankle, i.e. the tri-plane or Tillaux types [2]. The fragment is avulsed due to the strong anterior inferior tibiofibular ligament (originates from the anterolateral surface of the distal tibia and runs obliquely and inferiorly to the distal fibula) in supination external rotation injury

of the foot in relation to the leg [3,4] (Fig.1 (a) and (b)). This injury is rarely seen in adults, because the ligament firstly gives way instead of avulsing the tibial fragment from its epiphyseal attachment, resulting in a ligament injury known as a Tillaux lesion. This is a Salter–Harris type III epiphyseal injury [5,6]. Complaints were ankle swelling, lateral ankle bruising, and anterolateral ankle pain with inability to bear weight. Patient always denied any previous ankle fracture or injury. Tillaux fractures if not properly treated can cause pain or stiffness for up to 2 years after the injury, with joint incongruity resulting in degenerative arthritis, varus deformity, rotational deformity (rare), nonunion, delayed union (rare), and leg-length inequality (extremely rare) [2,4].

We present a case series of adolescent displaced Tillaux fractures, which was carried out exclusively surgically and led to an excellent outcome at the age of growth cessation.

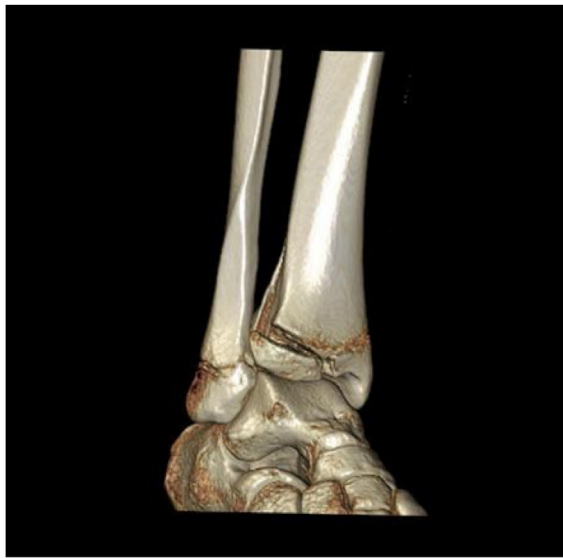2. Patient and methods

After approval by our institutional ethical committee, this prospective cohort study was done between May 2013 and May 2016 at our institution. This study was carried-up on 13 patients with 13 consecutive juvenile Tillaux fractures. All patients were

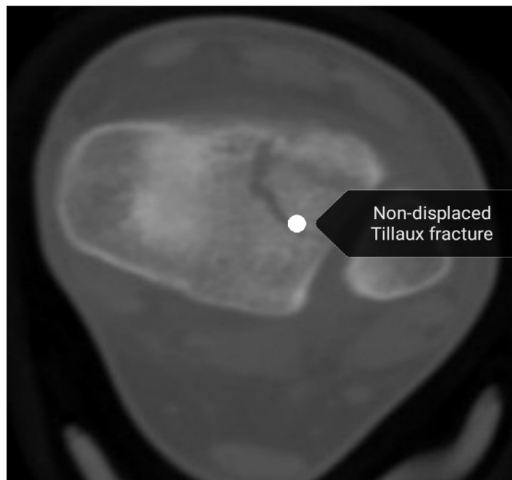
[☆] The study was approved by the local ethical committee and the patients were informed about the publication.

* Corresponding author at: Benha University Hospital, Orthopedics Surgery and Traumatology Department, Qualubia, Benha, Egypt.

E-mail addresses: mohamed.alsayed03@fmed.bu.edu.eg (M.E. Ali Al-Ashhab), ashraf.mohamed@med.tanta.edu.eg (A.A. Mahmoud Mohamed).



(a)



(b)

Fig. 1. (a) 3D CT scan showing Tillaux fracture. (b) Axial CTscan of non-displaced Tillaux fracture.

followed-up (ranged 60–24 m) with a mean 41.7 months. Patient's age ranged (12–17 years) with an average 13.4 years. Of those 13 patients, there were 9 females (69.2%) and 4 males (30.8%). Right side was affected in 6 patients (46%), while the left was affected in the remnant 7 patients (54%). There was no associated fracture in all patients. Mechanism of trauma in all patients was twisting ankle injury. Time elapsed between trauma and surgical interference ranged (1–7 days) with an average 5.4 days. Diagnosis was based on clinical and recognized by radiological criteria (X-ray views and CT scans) for all cases. From those 13 patients there were 4 initially non-displaced Tillaux fracture, but on the follow-up i.e. (the 1st visit, after one week from the initial trauma), follow-up X-rays and CT scans demonstrated displacement more than 2 mm, so those 4 patients were included within the surgically operated patients. All patient weights were appropriate regarding their age and heights, while there were 5 girls who showed marked overweight. All patient information, disease-, and treatment-related data were retrieved by a review of the patients' charts.

American Orthopedics Foot and Ankle Society score system (AOFAS score) [7] of the ankle joint was recorded.

3. Inclusion criteria

- 1-Adolescent age group. i.e. (12–17 years).
- 2-Simple (closed fractures).
- 3-Displacement is greater than 2 mm [8,9].

4. Operative technique

Skin condition was monitored and surgical decision was delayed until skin condition becomes suitable. General or regional anesthesia was used according to anesthesiologist decision. Tourniquet inflation under complete aseptic measures was started followed by appropriate draping. Closed reduction was tried in all patients in the form of internally rotating the foot (the pronated foot is internally rotated in plantar-flexion, with direct pressure applied to the anterolateral epiphysis) [2]. If this maneuver failed to achieve anatomic reduction, a joy-stick technique using a 3 mm Steinman pin was commenced till anatomical reduction was obtained and confirmed under fluoroscopy. In those who closed reduction could not be obtained i.e. (3 patients in this study), fractures were approached through an anterolateral ankle incision (between peronei and extensor digitorum tendons after incising the extensor retinaculum). A small capsulotomy was made in the anterolateral ankle, allowing visualization of the epiphyseal fragment after dividing the extensor digitorum brevis muscle in the direction of its fibers. In all cases, the fragment was secured with 4 mm partially threaded cancellous screw directed horizontally into the epiphysis and care was taken not to cross the physis. Fluoroscopy was used to make sure for the screw position. Closure of the wound was commenced.

5. Post-operative regimen

All closely managed Tillaux fractures were secured by a below the knee cast for 6 weeks with restriction of weight bearing. After cast splitting, physiotherapy was commenced. In the three open reduction operated patients, a below the knee slab was used for 2 weeks followed by sutures removal and application of a new below the knee cast for another 4 weeks. Patients were followed-up very closely every week until cast immobilization was over and then at 3-month intervals until full mobilization was possible.

6. Results

The results of this study can be assessed either clinically or radiologically

1-*Radiologically*: during follow-up, X-rays were done. Fractures were considered as consolidated when X-ray check-ups in all projections showed the significant presence of trabeculation crossing the fracture, without pain. All fractures were united with a union rate 100%. Union appeared radiologically between 6–8 weeks post-operatively with an average 6.3 weeks. There was no recorded case that needed screw removal.

2-*Clinically*: clinical assessment was obtained using the American Orthopedic Foot and Ankle Society (AOFAS) score of the ankle joint [7]. Overall average score was 97 ranged 95–100 (Table 1).

Regarding to post-operative complications, there was no recorded case of wound complications, no soft tissue or bone infections, and no neurovascular injuries using the closed maneuver or the anterolateral approach of the ankle joint. Case no. (1): Figs. 2–6..

Table 1
Case summary.

No.	Age	Gender	Side	Weight (kg)	Follow-up	Final score (AOFAS)
1	12	F	R	30	60 m	95
2	13	F	R	70	55 m	96
3	15	M	L	42	52 m	100
4	12	F	L	31	50 m	96
5	14	F	L	78	48 m	95
6	12	M	L	39	45 m	100
7	13	F	R	68	42 m	96
8	17	M	L	65	40 m	98
9	14	M	R	55	36 m	97
10	13	F	L	77	33 m	95
11	14	F	L	75	30 m	100
12	12	F	R	32	27 m	97
13	13	F	R	78	24 m	96

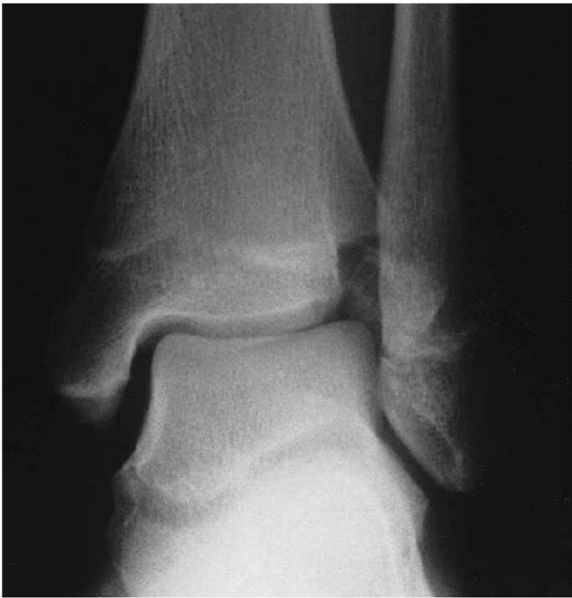

Fig. 2. Pre-operative AP X-ray ankle joint view showing displaced Tillaux fracture.

7. Discussion

The term Tillaux fracture was firstly described by Paul Jules Tillaux in 1892 who described a fracture of the anterolateral distal tibial epiphysis that is commonly seen in adolescents [10,11]. A similar injury to the posterolateral tibia was later described by Chaput and has been called the fracture of Tillaux-Chaput [10]. In spite of the relatively long introduction at this work, we found that

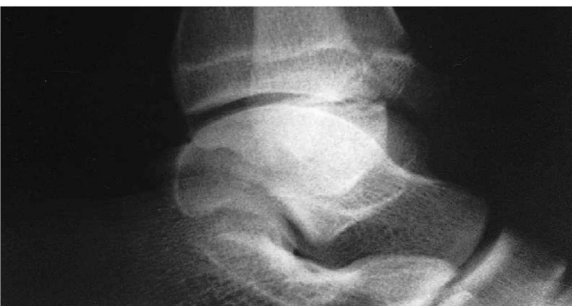

Fig. 3. Pre-operative lateral X-ray ankle joint view showing displaced Tillaux fracture.

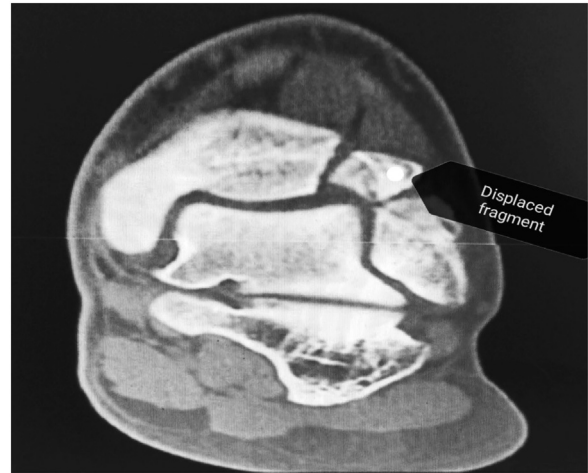

Fig. 4. Pre-operative coronal CT scan of ankle joint showing displaced Tillaux fragment.

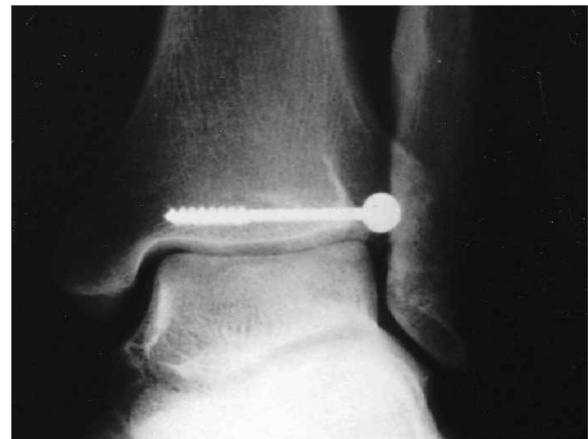

Fig. 5. One year post-operative AP X-ray view showing proper union without arthrosis.

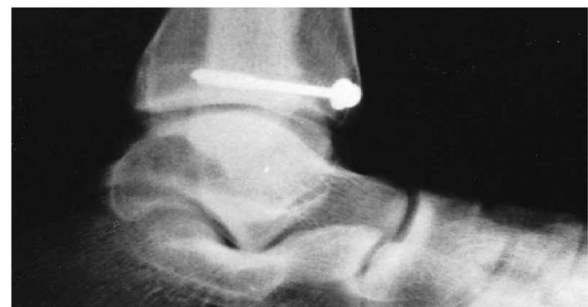

Fig. 6. One year post-operative lateral X-ray view showing proper union without arthrosis.

it is of paramount importance to mention more about the nature of the distal tibial epiphysis and its closure sequence to make the reader able to understand the mechanism through which Tillaux fracture can occur. Due to rarity of Tillaux fracture, a review of the literature revealed only a few studies dealing with this type of fracture and most of them were case reports or small number case series [12–14]. We reported on one of the largest case series of

patients with displaced Tillaux fractures treated in one single institution.

The juvenile “Tillaux” fracture was found in a specific age group and may be misinterpreted as a simple sprain if proper examination and investigations were not performed [15–17]. Tillaux fractures have a high affinity to displace, so close monitoring and close follow-up of the non-displaced fractures should be commenced to avoid malunion and further complications. Herein this study, four patients (30.7%) were initially non-displaced, but after 1 week, the fracture becomes displaced more than 2 mm and met our inclusion criteria. From those 13 patients there were 3 patients (23%) who could not obtain a closed reduction, so an anterolateral ankle approach was used.

Anatomical reduction is required in every displaced Tillaux fracture, especially in cases with ≥ 2 mm fragment displacement. Absolute anatomical fracture reduction and internal fixation can prevent a bone bridge and a consecutive epiphysiodesis with axial malalignment and limb length discrepancy, resulting in excellent clinical and radiological results [12,14].

In this work we noticed that Tillaux fracture occurred in 5 patients (38.4%) who were overweighted. Zonfrillo et al. [18] conducted a case control study, including 180 children with non-specified ankle injuries and 180 control subjects, and found a significant ($p < 0.0001$) association between overweight children (a BMI percentile of ≥ 95) and ankle injury.

This finding can be explained by the fact that, increased uptake of starch in today’s youth and subsequent decrease in protein intake decreases the body ability to restore osseous and soft tissue structure. Also, decrease in dietary intake of calcium, which is often replaced with carbonated beverages results in a weakening of osseous structures and predisposes these patients to fractures. Muscular development can impact the traction on growth centers and result in avulsion injuries [19]. Also fractures could be happened due to increased forces with normal bone.

Regarding to the short term results of this work, all patients presented with an excellent (AOFAS) score at the last follow-up (range was 95–100 with an average 97). There was no recorded post-operative complication. This finding is in agreement with Kaya et al. [10] who reported excellent results at 32–75 months of follow-up for 10 fractures with > 2 mm of displacement that were treated operatively. At the latest follow-up mean score was 99.3 (97–100) by the score of American Orthopaedic Foot and Ankle Society. Radiographically all fractures had healed in anatomical position. Tiefenboeck et al., had a Foot and Ankle Score 96.71 (< 1 year postoperatively) [3].

8. Limitations of the study

Although our series is one of the largest series of the literature and one of the series with longest follow-up, we believe that a larger series with longer follow-up and with control groups are necessary for more strict conclusions.

9. Conclusion

Our study shows that anatomically reduced Tillaux fractures at adolescent age group either by closed or opened means, followed by post-operative plaster cast immobilization will lead to excellent results.

Conflicts of interest

The authors declared no potential conflicts of interest with respect to the research, authorship, and/or publication of this article.

Funding

The authors received no financial support for the research, authorship, and/or publication of this article.

References

- [1] Tiefenboeck TM, Binder H, Joestl J, Tiefenboeck MM, Boesmueller S, Krestan C, et al. Displaced juvenile Tillaux fractures: surgical treatment and outcome. *Wien Klin Wochenschr* 2017;129(March (5–6)):169–75.
- [2] Panagopoulos A, van Niekerk L. Arthroscopic assisted reduction and fixation of a juvenile Tillaux fracture. *Knee Surg Sports Traumatol Arthrosc* 2007;15(April (4)):415–7.
- [3] Crawford AH. Triplane and Tillaux fractures: is a 2 mm residual gap acceptable? *J Pediatr Orthop* 2012;32(Suppl. 1):S69–73.
- [4] Spiege LPG, Cooperman DR, Laros GS. Epiphyseal fractures of the distal ends of the tibia and fibula. A retrospective study of two hundred and thirty-seven cases in children. *J Bone Joint Surg Am* 1978;60(8):1046–50.
- [5] Horn BD, Crisci K, Krug M, Pizzutillo PD, MacEwen GD. Radiologic evaluation of juvenile Tillaux fractures of the distal tibia. *J Pediatr Orthop* 2001;21(2):162–4.
- [6] Leetun DT, Ireland ML. Case report arthroscopically assisted reduction and fixation of a juvenile Tillaux fracture. *Arthroscopy* 2002;18(April (4)):427–9.
- [7] Kitaoka HB, Alexander IJ, Adelaar RS, Nunley JA, Myerson MS, Sanders M. Clinical rating system for the ankle-hindfoot, midfoot, hallux, and lesser toes. *Foot Ankle Int* 1994;15(7):349–53.
- [8] Kaya A, Altay T, Ozturk H, Karapinar L. Open reduction and internal fixation in displaced juvenile Tillaux fractures. *Injury* 2007;38(2):201–5.
- [9] Rosenbaum AJ, DiPreta JA, Uhl RL. Review of distal tibial epiphyseal transitional fractures. *Orthopedics* 2012;35(12):1046–9.
- [10] Koury SI, Stone CK, Harrell G, La Charité DD. Recognition and management of Tillaux fractures in adolescents. *Pediatr Emerg Care* 1999;15(February(1)):37–9.
- [11] Kumar N, Prasad M. Tillaux fracture of the ankle in an adult: a rare injury. *J Foot Ankle Surg* 2014;53(November–December (6)):757–8.
- [12] Steinlauf SD, Stricker SJ, Hulén CA. Juvenile Tillaux fracture simulating syndesmosis separation: a case report. *Foot Ankle Int* 1998;19(May(5)):332–5.
- [13] Leary JT, Handling M, Talerico M, Yong L, Bowe JA. Physeal fractures of the distal tibia: predictive factors of premature physeal closure and growth arrest. *J Pediatr Orthop* 2009;29(4):356–61.
- [14] Lu J, Helledge MM. Tillaux and Volkmann fractures: a report on two cases, treatment determined by syndesmosis instability. *Trauma Cases Rev* 2016;2(4) 1–5 2:042.
- [15] Blanca Schuster B, Mayr J, Enrico Bronnimann E. Uncommon injury of the distal tibial epiphysis in a child: a case report. *Trauma Acute Care* 2017;2(5) 58. pp. 1–3.
- [16] Okur A, Nakşllar F. Juvenile Tillaux fractures. *Acta Orthop Traumatol Turc* 1995;29:321–3.
- [17] Blackburn EW, Aronsson DD, Rubright JH, Lisle JW. Current concepts review, ankle fractures in children. *J Bone Joint Surg Am* 2012;94:1234–44.
- [18] Zonfrillo MR, Seiden JA, House EM, Shapiro ED, Dubrow R, Baker MD, et al. The association of overweight and ankle injuries in children. *Ambul Pediatr* 2008;8 (January–February (1)):66–9.
- [19] Premaor MO, Comim FV, Compston JE. Obesity and fractures. *Arq Bras Endocrinol Metabol* 2014;58(July (5)):470–7.